



Original article

Influence of resveratrol on liver fibrosis induced by dimethylnitrosamine in male rats

Suzan B. Abdu*, Fatima M. Al-Bogami

Department of Biological Sciences, Faculty of Sciences, King Abdulaziz University, P.O. Box 80200, Jeddah 21589, Saudi Arabia

ARTICLE INFO

Article history:

Received 20 March 2017

Revised 3 May 2017

Accepted 20 September 2017

Available online xxx

Keywords:

Dimethylnitrosamine

Liver fibrosis

Resveratrol

Antifibrotic role

Rats

ABSTRACT

Liver fibrosis is a significant health problem which represents the liver's scarring process and response to injury through deposition of collagen and extracellular matrix, and ultimately leads to cirrhosis. Resveratrol is a naturally occurring phytoalexin found predominantly in grapes. This study aimed to investigate the antifibrotic role of resveratrol on dimethylnitrosamine (DMN)-induced liver fibrosis in rats. Rats were divided into four groups and treated for three weeks; control, resveratrol administered orally (20 mg/kg daily), DMN intraperitoneally injected (10 mg/kg 3 days/week), and the last group was pre-treated daily with resveratrol then injected with DMN, 3 days/week. DMN administration induced severe liver pathological alterations. However, oral administration of resveratrol before DMN significantly prevented the induced loss in body weight, as well as the increase in liver weight which arise from DMN administration. Resveratrol has also inhibited the elevation of serum aspartate aminotransferase (AST), alanine aminotransferase (ALT), alkaline phosphatase (ALP) and bilirubin levels. Furthermore, resveratrol significantly increased hepatic reduced glutathione (GSH) levels and reduced the levels of malondialdehyde (MDA) due to its antioxidants effect as well as increased serum protein levels. In addition, DMN induced elevation in hydroxyproline content. On the other hand, hydroxyproline level was significantly reduced in the resveratrol pretreated rats. Resveratrol has also remarkably maintained the normal liver lobular architecture. Moreover, resveratrol had displayed potent potentials to prevent collagen deposition, lymphocytic infiltration, necrosis, steatosis, vascular damage, blood hypertension, cholangiocyte proliferation. It can be concluded that resveratrol has a marked protective role on DMN-induced liver fibrosis in rats, and can be considered as antiproliferative, antihypertensive, as well as antifibrotic agent and may be used to block the development of liver fibrosis.

© 2017 Production and hosting by Elsevier B.V. on behalf of King Saud University. This is an open access article under the CC BY-NC-ND license (<http://creativecommons.org/licenses/by-nc-nd/4.0/>).

1. Introduction

Liver fibrosis is a wound-healing response to chronic liver injury that leads to cirrhosis and liver failure if liver damage occurs frequently. Hepatic fibrosis is a widespread health problem with a worldwide mortality attributable to cirrhosis and primary liver cancer of around 1.4 million deaths per year (WHO, 2002). Liver go through wound healing processes when suffering from chronic injury, accumulate a mass of extracellular matrix proteins and

afterward, fibrosis or scarring occurs. Several etiologies, such as viral hepatitis, alcohol intoxication, drug abuse, metabolic disorders due to mineral overload, and autoimmune diseases, attribute to liver fibrosis (Kisseleva and Brenner, 2006; Sugimoto and Takei, 2017), which may later progress into cirrhosis. Liver cirrhosis commonly results in high mortality (Friedman, 2003) and consequently develops into hepatocellular carcinoma (HCC) (Bataller and Brenner, 2005).

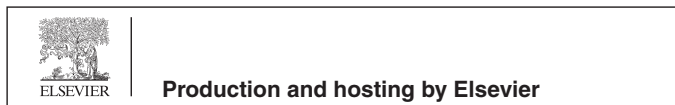Previously, liver fibrosis and cirrhosis were assumed to be irreversible responses whereas current thoughts hold otherwise, if the underlying etiology is eradicated (Zhou and Lu, 2009). During acute injury, the changes in liver architecture are reversible. With chronic injury, there is gradual replacement of the liver parenchyma by scar tissue. The liver has a remarkable regenerative capacity, subsequently, patients often progress slowly to cirrhosis over decades (Lee and Friedman, 2011).

Fibrosis leading to cirrhosis can accompany nearly any chronic liver disease that is characterized by disruption and/or inflammation

* Corresponding author.

E-mail addresses: sabdu@kau.edu.sa, suzanabdu3@gmail.com (S.B. Abdu).

Peer review under responsibility of King Saud University.



of tissue architecture. Mortality is higher because cirrhosis influences the progress of HCC, which represents the fifth most common cancer and the third most common cause of cancer mortality worldwide. Epidemiological investigation predicts a peak for advanced chronic liver diseases (CLDs), including HCC, in the next decade with an expanded number of patients getting end-stage disease (Parola and Pinzani, 2009). Currently liver transplantation is the main suitable treatment for end-stage liver disease, which implies that new therapies for liver fibrosis are urgently needed (Forbes and Parola, 2011).

Reactive oxygen species (ROS) are harmful to cells, mainly due to the destructive effect they exert on lipids, proteins and nucleic acids, which lead to structural and functional damage (Birben et al., 2012; Al-Attar and Al-Retha, 2016). ROS cause liver damage through lipid peroxidation, resulting in inhibition of mitochondrial and peroxisomal β -oxidation enzymes, leading in turn to accumulation of fatty acids in the hepatocytes, resulting in hepatic steatosis (Reddy and Rao, 2006). Numerous interventions have been proposed to counteract the effects of ROS by boosting the antioxidant defense systems.

Plants produce a large number of low-molecular-weight natural products as 'secondary metabolites' play a critical role in the defense of plants against infections or stress-inducing conditions. When plants are assaulted by pathogenic organisms, Phytoalexins are produced (Borriello et al., 2010). Resveratrol (3,5,4'-trihydroxystilbene or 3,5,4'-stilbenetriol; MW: 228.25) is a polyphenol identified as a phytoalexin and caught remarkable attention. Resveratrol is synthesized by several plants in response to adverse conditions such as stress, injury, UV irradiation and fungal infection (Floreani et al., 2003). Resveratrol is produced by several plant species, such as grapes, mulberries and peanuts. Epidemiological investigation on the French paradox phenomenon laid the earliest findings on the beneficial impact of resveratrol to the human body. That the frequency of coronary heart diseases in France was much lower than those in different nations, despite the French had high-fat diets (Ndiaye et al., 2011). In addition to the cardioprotective properties, resveratrol have the ability to exert vasorelaxation, anti-inflammatory response, and ROS scavenging (Khurana et al., 2013). Among other health benefits, resveratrol possesses anti-tumor, anti-diabetic and anti-obesity activities (Brisdelli et al., 2009; Jeong et al., 2012; Li et al., 2012). Currently, resveratrol is generally extracted from red grapes, and it has been estimated that fresh grape skin contains about 50–100 μ g of resveratrol/g (Timmers et al., 2012).

Resveratrol has been found to improve endothelium-dependent vasodilation due to its power to enhance endothelial NO production, to increase endothelial nitric oxide synthase (eNOS) expression in mouse arteries (Wallerath et al., 2002), implying that resveratrol could lower blood pressure. Additionally, resveratrol can induce major anti-oxidant enzymes (e.g. glutathione peroxidase, heme oxygenase, superoxide dismutase) in cardiac and vascular cells (Das et al., 2006; Thirunavukkarasu et al., 2007; Ungvari et al., 2010) which lead to a marked reduction of oxidative stress.

Recently, resveratrol has been recognized as an antiaging compound which can be applied in neurodegenerative disease therapy. On animal models, resveratrol has shown its effects on Alzheimer's disease (AD), Parkinson's disease (PD), Huntington's disease, amyotrophic lateral sclerosis, and neuropathic pain (Rosen et al., 1993; Gao and Hu 2005; Solans et al., 2006; Sharma et al., 2007; Singh et al., 2007). For Parkinson's disease, resveratrol (10–40 mg/kg/d) given orally for 10 weeks, significantly protects dopaminergic neurotoxicity in substantia nigra in 6-hydroxydopamine induced PD in rats (Jin et al., 2008). Resveratrol can also be utilized to treat acute seizures (Shetty, 2011). Furthermore, resveratrol has anti-bacterial effects (Docherty et al., 2007).

Dimethylnitrosamine (DMN) is a potent hepato-carcinogen and mutagen, induces not only liver fibrosis but also cirrhosis due to repeated exposure of animals to its lower dosages (Ahmad et al., 2009). Therefore, establishing effective anti-fibrotic strategies may alter the natural history of chronic liver disease and ultimately manage liver fibrosis and cirrhosis, bringing hope to millions of patients with chronic liver disease worldwide. For this reason, this study is aiming to capture the main advances in liver fibrosis histology, and provide the rationale for antioxidants potentials of resveratrol in the prevention of liver fibrosis.

2. Materials and methods

2.1. Animals

Twenty-eight Wistar male albino rats weighing 90–116 g were used in the experiment in accordance with the guidelines of the Biochemical and Research Ethical Committee at King Abdulaziz University, Jeddah, Saudi Arabia. Animals were housed in a well-ventilated temperature-controlled room at 22 ± 23 °C with 12 h light and dark cycles. Food consisted of standard laboratory rat chow with free access to water. All experimental procedures were performed between 8 am and 11 am and care was taken to avoid all stressful conditions.

2.2. Study design

Animals were randomly divided into four groups.

Group 1 (control group): Rats were treated orally with the volumes of saline and 0.5% CMC solution equivalent to those of the resveratrol group, for 3 weeks.

Group 2 (resveratrol group): Rats were treated orally with (20 mg/kg body weight/day) for 3 weeks. Resveratrol suspended in 0.5% carboxymethylcellulose sodium CMC (Lee et al., 2010).

Group 3 (fibrosis group): liver fibrosis was induced by intraperitoneal injection (i.p.) of DMN (10 mg/kg body weight/day) on three consecutive days of each week for 3 weeks. DMN 10 μ l diluted to 1 mL with 0.15 M sterile NaCl (Lee et al., 2003).

Group 4 (protection group): Rats were given resveratrol (daily), then after 2 h lag were treated with DMN (3 days/week) for 3 weeks. 2 h lag of resveratrol administration was selected on the basis of (Ahmad and Ahmad, 2014).

The morphological and behavioral changes were monitored after administration of DMN. Animals were weighed at the beginning of the experiment, and each week. On day 0, 7, 14, and 21. Animals were anaesthetized and sacrificed on day 21st from the beginning of the experiment.

2.3. Sample collection and preparation

The body weight and liver weight of the animals in each group were measured. Before sacrifice, blood samples were obtained from orbital vein on day 21st from all groups. Blood samples were centrifuged at 3000 rpm and 4 °C for 8–10 min. and the resulting clear, pale colored sera was stored in aliquots at -20 °C for biochemical analysis. The animals were sacrificed at the end of the third week under ether anesthesia. The livers of all animals were rapidly removed rinsed in cold saline and weighed. Liver tissue was fixed in formalin for histopathological study, the remaining tissue stored at -20 °C until assayed.

2.4. Preparation of liver homogenate

Liver tissue was homogenized in 1:3 (w/v) Tris–HCl buffer (50 mM, pH 7.5) at 4 °C. The final concentration of the homogenate was adjusted to 100 mg tissue/ml (Potters B.BRALUN type: 853304/0). The crude homogenates were centrifuged at 8000 rpm and 4 °C for 30 min (BECKMAN model J2-21). The supernatant was used for biochemical assays.

2.5. Assay of liver function biomarkers

The activities of biomarkers of liver function were determined using Siemens Dimension Vista® system. The activities of aspartate aminotransferase (AST) and alanine aminotransferase (ALT) were assayed by the method of Bergmeyer et al. (1978). The activities of alkaline phosphatase (ALP) were determined according to the protocol described in Bowers and McComb (1966). Bilirubin was assayed by the method of Doumas et al. (1985).

Hydroxyproline collagen (fibrosis markers expression) was measured using manual kit (Elisa BIOTEK, Synergy HT). Hepatic reduced glutathione (GSH) level was determined by the method of Tietze (1969). Malondialdehyde (MDA) was measured using the method of Ohkawa et al. (1979).

2.6. Histopathological examinations

The liver specimens were fixed in 10% neutral buffered formalin for histological study by light microscopy (Bancroft and Gamble,

2002). 3–5 µm liver sections were deparaffinized and processed routinely for hematoxylin and eosin (H&E) and Masson's trichrome staining.

2.7. Statistical analysis

Values for weight and biochemical data are expressed as mean value ± SD. Statistical analysis was performed by one-way analysis of variance (ANOVA) using SPSS 16.0 software (SPSS Inc., USA). Statistical significance was estimated by *t*-test. $P < 0.05$ was considered statistically significant.

3. Results

3.1. Body and liver weights

The body weight of all groups is represented in (Fig. 1). In DMN treated group, the ratio of the total increase in body weight was significantly low (44.9%) compared to the other groups (88.5%, 83.3%, and 91.8% in G1, G2 and G4 respectively). However, in relative liver weight DMN treatment caused the highest increase (5.8%) compared to other groups (5.2%, 4.9%, 5.5% G1, G2 and G4 respectively) (Fig. 1). Interestingly, in resveratrol group (G2) the ratio of the total increase in body weight was lower than the control group, and the relative liver weight was the lowest compared to other groups. Our results show that resveratrol pretreatment tended to suppress the loss of body weight as well as the increase in relative liver weight.

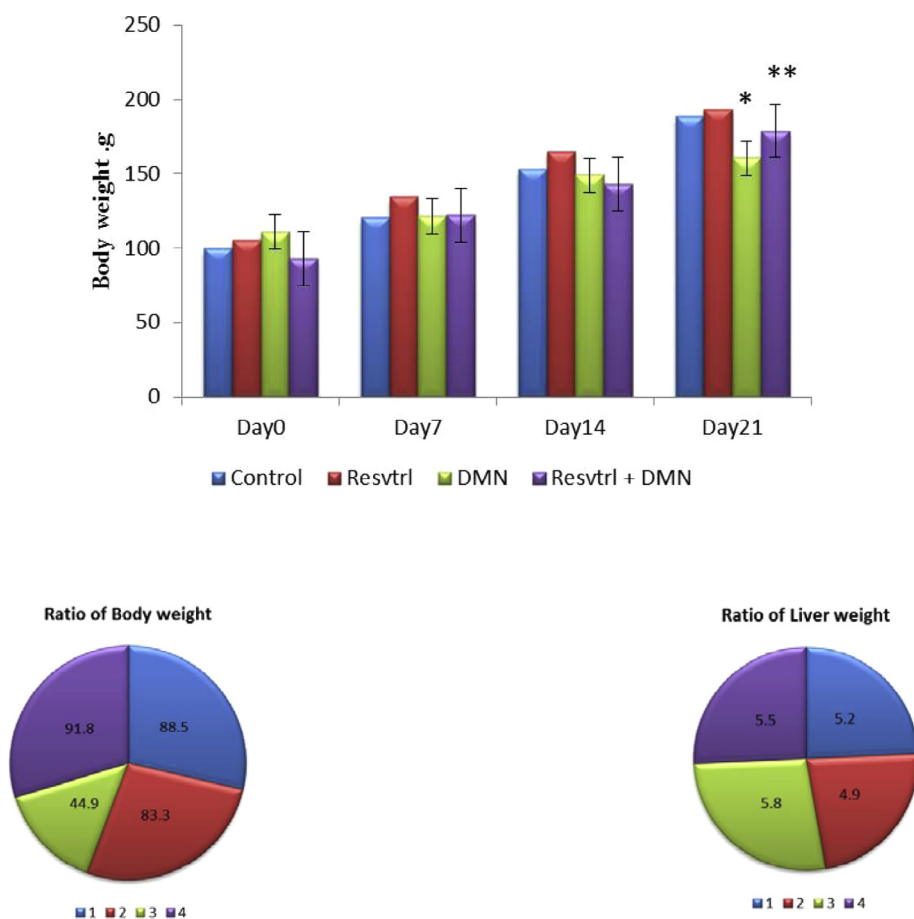


Fig. 1. Body and liver weights of all experimental groups. Statistical analysis of rats body and liver weights during DMN intoxication (G3) and resveratrol (Resvtrl) pretreatment (G4). Body and liver weight were measured weekly throughout the study. Results were analyzed by ANOVA one way and are presented as mean ± SEM $P \leq 0.01$. * indicates a significant difference between G1 and G3. ** indicates a significant difference between G3 and G4.

Ratio of the total increase of b. wt.

$$= \frac{\text{final b. wt.} - \text{original b. wt.}}{\text{original b. wt.}} \times 100 \quad (1)$$

$$\text{Relative liver wt.} = \frac{\text{liver wt.}}{\text{b. wt.}} \times 100 \quad (2)$$

3.2. Serum parameters of liver function

After 21 days, the levels of serum AST, ALT, ALP were shown in Fig. 2. In the DMN-intoxicated group, activities of serum AST, ALT

and ALP (126.60 ± 12.32 , 69.80 ± 15.155 , 291.20 ± 40.98 respectively) were higher than the control group (119.80 ± 11.69 , 59.00 ± 28.61 , 249.80 ± 115.73). Resveratrol pre-treatment reduced these DMN-induced elevations (111.40 ± 11.80 , 53.60 ± 6.348 , 200.40 ± 48.438). Excretion of bile pigments can be impaired after liver damage. Pre-treatment with resveratrol (2.40 ± 0.547) inhibited the increases in the serum bilirubin content in rats treated with DMN (2.60 ± 0.547). The total sera protein contents were significantly decreased in DMN group (63.40 ± 2.30) indicating DMN-mediated disruption in protein synthesis in the liver, when compared to control values (67.60 ± 1.14). Resveratrol pre-treatment significantly blocked these reductions in serum

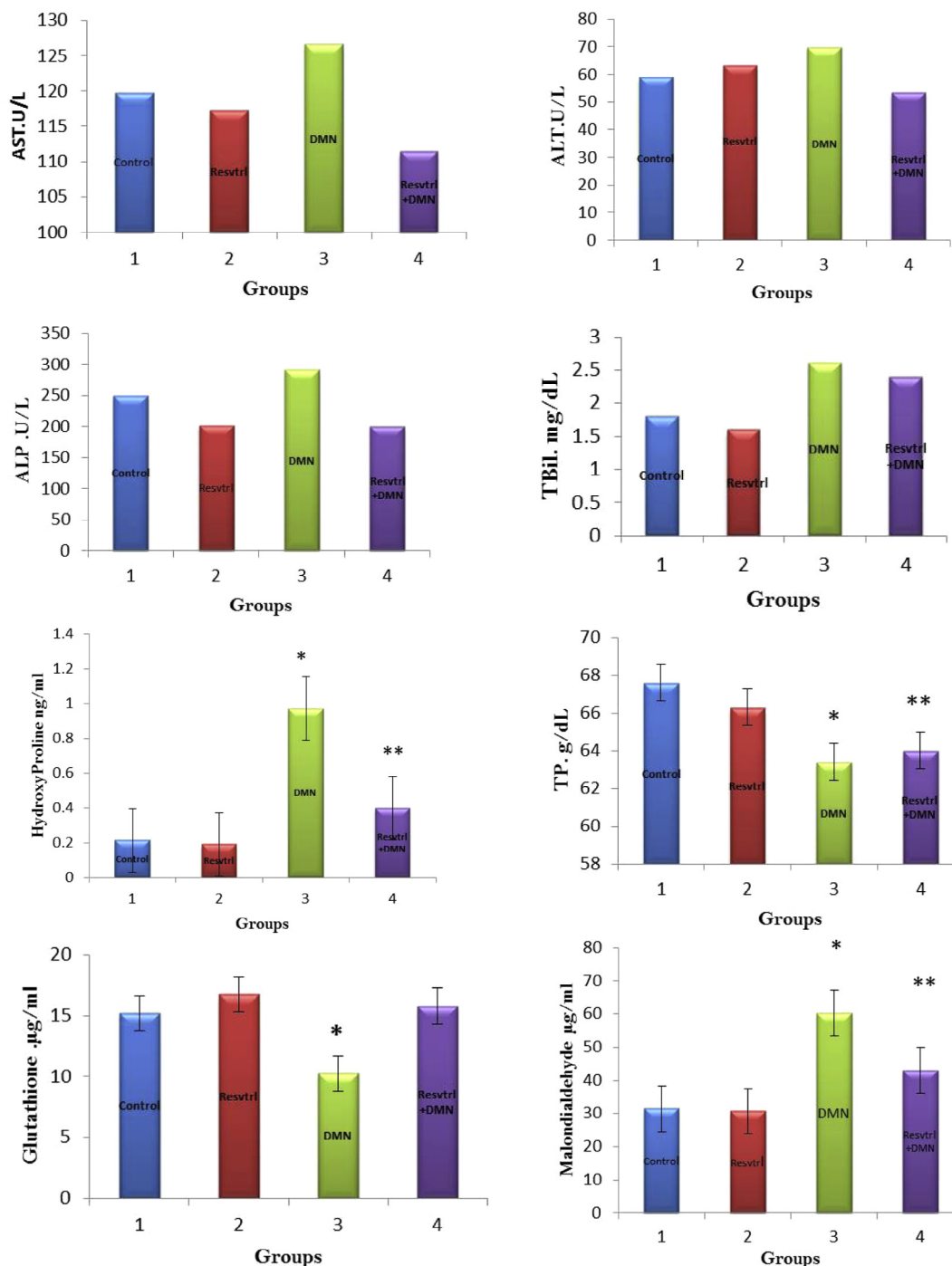


Fig. 2. Serum and homogenate levels of liver biomarkers. The mean difference is significant at the 0.05 level by ANOVA one way $p \leq 0.05$. * indicates a significant difference between G1 and G3. ** indicates a significant difference between G3 and G4.

protein concentrations and ameliorated the protein synthesis in G4 (64.00 ± 2.00). Resveratrol pre-treatment at a dose of 20 mg/kg was significantly effective in revising all enzymatic variables towards normal as evidenced by t-test ($P < -0.05$) (Fig. 2).

3.3. Liver homogenate parameters

Hydroxyproline, an amino acid exclusively present in collagen, the levels of hydroxyproline in liver homogenate were found to be significantly elevated during DMN-intoxication (97 ± 0.226). On the contrary, the resveratrol pre-treatment significantly minimized the DMN-induced elevated hydroxyproline contents of liver (0.398 ± 0.286), suggesting a decline in collagen deposition (Fig. 2). GSH level as measured in the liver tissue of all the experimental groups has been shown in (Fig. 2). DMN administration caused massive reduction in liver GSH level (10.256 ± 2.026). Pre-treatment with resveratrol elevated that reduction (15.78 ± 4.46). The level of MDA as an index of lipid peroxidation, a degradative process of membrane lipids, in liver tissue of DMN treated rats was significantly ($P < 0.01$) elevated (60.196 ± 20.34) when compared to control animals (31.51 ± 17.64). Pre-treatment with resveratrol significantly decreased the elevation of MDA (42.98 ± 1.35). According to data shown in Fig. 2 Pre-treatment with resveratrol was significantly effective in retaining all the measured parameters (G4) at normal levels as evidenced by Student's t-test ($P \leq 0.05$).

3.4. Histological study

Light microscopic study of the control liver (G1) showed normal liver architecture with portal areas demarcated by connective tissue. Normal amount of collagen fibers was observed at the portal area. At the center of the lobule is the central vein, into which the sinusoids drain. Anastomosing plates of hepatocytes, separated by sinusoids that perfuse the cells with the mixed portal and arterial blood were radiated from the central vein. The hepatocyte has one or two nuclei (Figs. 3 and 4A). In resveratrol group (G2), the histology was virtually the same as the control with normal lobular structure (Figs. 3 and 4B). Administration of DMN for 21 days induced severe histopathological changes in the liver tissue (G3). Masson's trichrome stain demonstrated dilatation of central veins with slight pericentral fibrosis and well developed portal fibrosis. Collagen deposition was distinct on day-21 of DMN treatment (Fig. 3C). Sections has fibrous, disorganized portal tracts with bridging fibrosis and extensive proliferation of the bile ducts (duct hyperplasia), a large number of small bile ducts and a smaller number of large dilated bile ducts were seen as well as multiple bile ductules in the periphery of a portal area (Fig. 3E). H&E staining showed distinct vascular thrombosis in many portal veins, focal congestion and hemorrhage with marked dilatation and deformation of central and portal veins (Fig. 4C). Early cirrhosis was noticed in some areas owing to the portal tracts expansion by inflammatory cells. As liver cells were destroyed, the portal tracts became extended by fibrosis. Lymphocytic inflammation and damage extended to bile ducts in portal tracts. Many portal tracts appeared to have enlarged arteries and ducts (Fig. 3E) Fig. 4c. In addition, numerous irregular arterial branches, visible arterial sprouting was observed along with dilatation of portal veins. Severe disruption of vascular architecture such as obliterative portal venopathy (Fig. 4C) was evident. Thickening of the central vein wall was seen in many areas. Thrombi were common (Fig. 4C), hepatic small vessels showed signs of vasculitis and wall thickening with frequent vascular thrombosis (Fig. 4E). Infiltration of mononuclear cells was observed in portal tracts. Inflammatory lymphocytes may also be present in hepatic parenchyma within sinusoids. Widespread ballooning of hepatocytes owing to hydropic degeneration was evi-

dent (Fig. 3E). Spotty necrosis, small aggregates of inflammatory cells of lymphocytes and activated Kupffer cells/macrophages in the lobule was seen (Fig. 3E). Necrosis is characterized by cell swelling, karyolysis, cell lysis, and release of cellular contents. The cytoplasm has lost definition and the plasma membranes are indistinct. Complete breakdown of nuclear material was seen and karyolysis was evident leaving the dead cell as an anucleate (Fig. 4E). Therefore, the liver parenchyma displayed several areas of hepatocyte suffrance represented by areas of cellular ballooning, vacuolar degeneration, steatosis, hemorrhage as well as spotty and single cell necrosis. Accumulation of eosinophilic material inside portal veins (Fig. 4G) as well as lipid droplets in many areas inside the portal veins, ducts and hepatocytes was noticed. Portal veins wall were replaced by a thick fibrous tissues.

The effect of resveratrol supplementation before DMN administration was documented. Using Masson's trichrome stain, fibrosis was noted during the treatment of rats with DMN with the deposition of collagen fibers surrounding the portal areas, central veins. Thickening and deposition of these collagen fibers was markedly reduced in resveratrol pre-treated rats (Fig. 3D and F). Resveratrol pre-treatment greatly suppressed the levels of necrotic liver damage by minimal inflammatory cells infiltration (Fig. 4D and F); spotty necrosis was extremely reduced as well as, single cell necrosis compared to DMN group. Regenerating hepatocytes were seen in many places. Fibrosis, vascular dilatation, congestion, wall thickening, duct proliferation, and necrosis were considerably ameliorated by resveratrol supplementation before DMN treatment. In contrary to DMN group, resveratrol preserved the portal vein wall structure normal. Eosinophilic material and steatosis in the portal area and hepatocytes were highly reduced compared to DMN group (Fig. 4H). Administration of resveratrol daily before DMN at 20 mg/kg maintained to a large extent the normal architecture of the liver. The histopathological alterations from DMN were remarkably reduced in the liver of this group. Resveratrol preserved almost normal lobular pattern with better cord arrangement of hepatocytes.

4. Discussion

Liver toxicity is one of the most important diseases in the world. Therefore, the efforts in the hepatoprotection and treatment of liver disorders are highly needed. DMN induced liver fibrosis in rats is one of the most extensively studied experimental model for clarifying the mechanism of liver fibrosis. The model imitates fibrosis in human liver. It is suitable for evaluating the efficacy and hepatoprotective potential of natural and synthetic compounds (Ahmad et al., 2014). The present study was conducted to evaluate the protective effect of resveratrol against DMN induced hepatic fibrosis.

The present study showed that resveratrol prevented the decrease in body weight as well as the increase in liver weight resulted from DMN administration. Oral administration of resveratrol was able to keep the damage to near normal biomarker levels and reserve histological integrity. Resveratrol supplementation significantly regulated the DMN mediated alterations in biomarkers of hepatic fibrosis. The AST, ALT and ALP are markers of hepatocellular injury (Wegwu et al., 2005) and their elevation in serum reveals cellular leakage and loss of the functional integrity of cell membranes in liver (Rajesh and Latha, 2004). Decline in AST, ALT and ALP levels after resveratrol administration indicated improvement in hepatocytes integrity. AST is indicative of necrosis. ALT is a cytosolic enzyme, an increase in enzyme activity reflects increase in cell membrane permeability which in turn associated with cell death (Rosen and Keeffe, 2000). ALP is a membrane bound enzyme and mainly arises from the lining of the bile canaliculi and

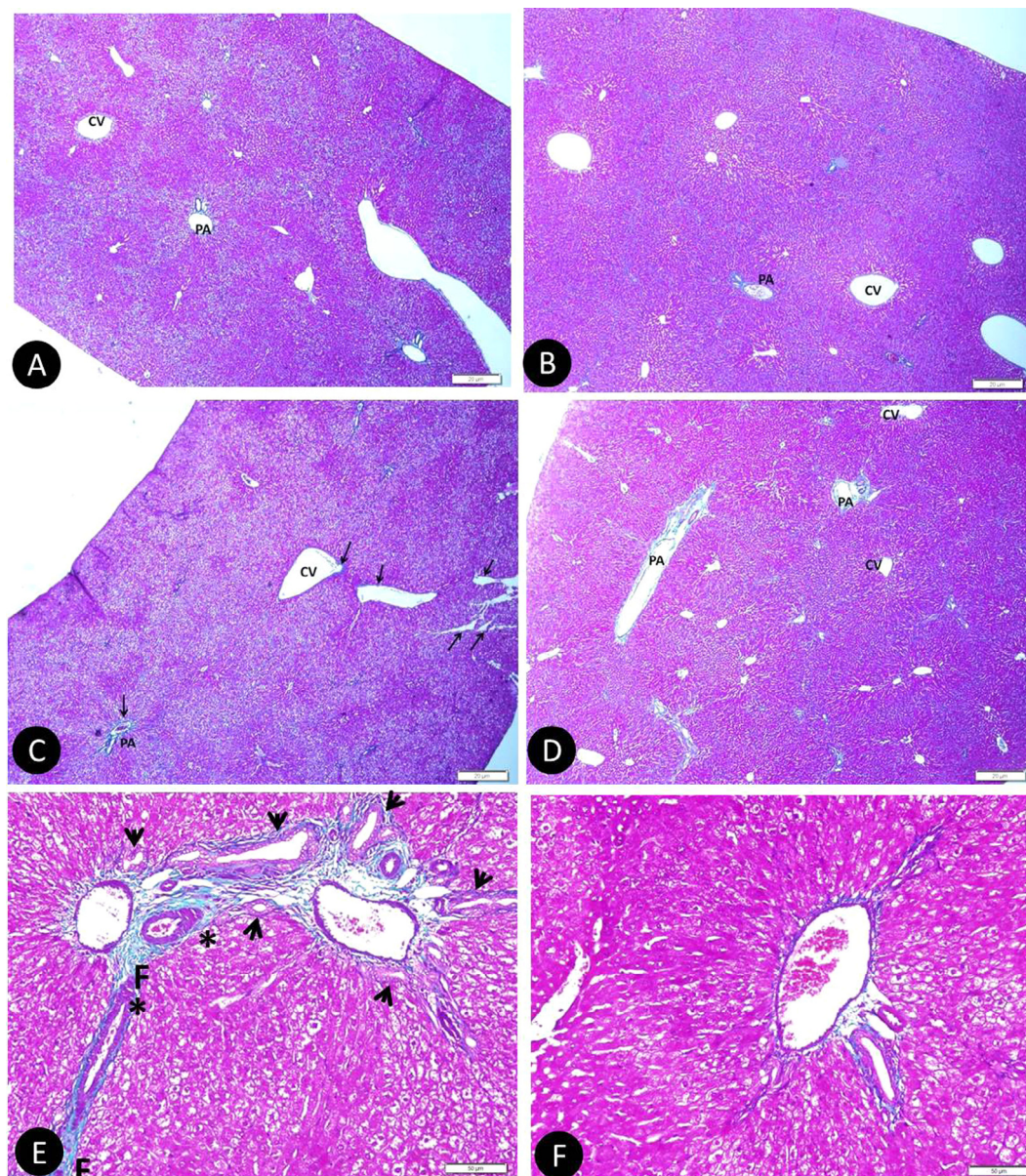


Fig. 3. Light micrographs of rat liver sections showing (A) control, (B) resveratrol, the histology is the same as the control with normal lobular structure; (C) DMN with central veins dilatation and disrupted vascular architecture (arrows), collagen deposition (stained in blue) around the central vein and portal area; (D and F) resveratrol pretreated group, exhibiting minimal fibrosis, with normal central veins and portal areas. Thickening of collagen fiber bundles and central vein dilatation is markedly reduced by resveratrol pretreatment. (E) DMN, bridging fibrosis between two portal areas with marked increase in collagen content. Note bile ducts proliferation (arrows) and muscular hypertrophy of a hepatic artery (*). Central vein (CV) and portal area (PA). Masson's trichrome stain (A, B, C and D X40; E and F X 200).

sinusoidal surface of hepatocytes that is excreted by the liver normally via bile (Muriel and Escobar, 2003). ALP is an indicator of cholestasis, interruption in the excretion of bile, caused by obstruction within the liver (Giannini et al., 2001). The obstruction causes bile salts, the bile pigment bilirubin, and fats to accumulate in the blood stream instead of being eliminated normally. The liver occupies a central role in the metabolism of bile pigments in the hepatic uptake, conjugation, and excretion of bile pigments which can be impaired after liver damage. Bilirubin is one of the most useful clinical parameters to know the severity of hepatic necrosis which is resulted from the degradation of hemoglobin and excreted into the bile. Resveratrol decreased the elevated level of serum bilirubin in the present study, suggesting that it can be used in the acute condition of jaundice (Fan et al., 2009). In addition, the decreased value of sera protein in DMN group suggesting a decrease in the synthesis of protein due to the necrosis that was noticed in this

group. On the other hand, this parameter was increased in resveratrol pretreatment suggesting amelioration in cell content and integrity.

Oxidative stress, either mediated by ROS or free radical species, results in the oxidative decomposition of membrane phospholipids that lead to the formation of end products such as malondialdehyde (MDA), 4-hydroxy-2,3-nonenal (HNE) and other 4-hydroxy-2,3-alkenals (Ahmad and Ahmad, 2014). ROS and free radicals, generated during cytochrome P450-mediated DMN metabolism, have strong potential to react with triglycerides of the hepatic biomembranes and would inflict peroxidative damage to produce lipid peroxides. Lipid peroxidation is a common event in any toxic phenomenon. It occurs to a limited extent under normal physiological conditions, but external factors can augment this process so that it escapes cell control which leads to damage of macromolecules such as lipids in the cell membrane and eventually

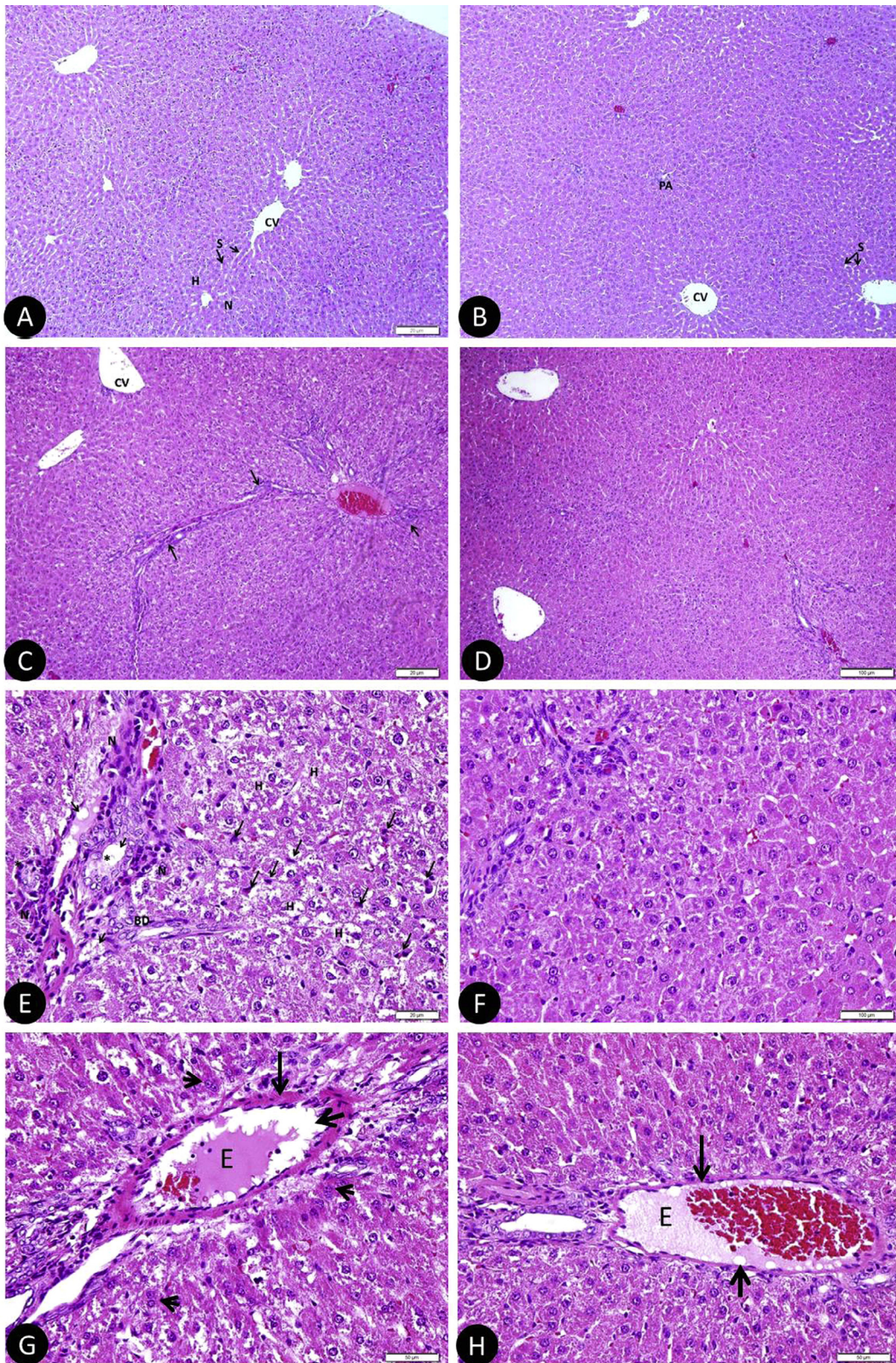


Fig. 4. Histological analysis of rat liver sections showing (A) control, normal liver structure with polygonal hepatocytes (H), prominent nucleus (N), sinusoids (S) and central vein (CV); (B) resveratrol treatment, normal structure with organized plates of hepatocytes separated by sinusoids (S). (C) DMN, early cirrhosis with dilated, congested portal vein and the extension of inflammatory cells from the portal tract into the periportal parenchyma (arrows). (D) Resveratrol pretreatment, tissue architecture appears to be similar to that of control rats. (E) DMN, typical lymphocytic inflammation spotty necrosis (N) and damage to bile ducts in portal tracts (*). Note, proliferation of bile ductules (BD), fat droplets (thick arrow) inside ducts, veins, and hepatocytes. Most of the hepatocytes (H) are swollen and hydropic, but some are shrunken and necrotic (arrows); (F) resveratrol pretreatment shows preserved and organized hepatocyte plates and sinusoids. Necrosis is rare. (G) DMN. Dilated and thickened fibrotic portal vein (arrow) with eosinophilic material (E) and large amount of fat droplets inside the vein (short arrow), hepatocytes show ballooning and steatosis. Note the large number of fibroblasts lining the vein wall, and liver cell regeneration (head arrows). (H) Resveratrol pretreatment. Note the big difference in the wall thickness of the portal vein between (G and H), the fat inside the vein, and the eosinophilic material. (H&E) stain (A, B, C, and D $\times 100$; E, F, G and H $\times 400$).

causes membrane damage and cell death (Chávez et al., 2008). Our data on liver of DMN-treated rats showed significant increase in MDA levels as well as a significant decrease in GSH levels. MDA parameter is an indicator of oxidative stress and disruption in hepatocytes membrane integrity. On the other hand, the significant depletion of MDA levels and elevation of GSH levels in resveratrol pretreated animals may reflect a decrease in lipid peroxidation and increase in tissue antioxidant defense enzymes. This indicates that resveratrol could reduce the generation of free radicals as well as boost the free radical scavenging mechanism. Resveratrol has previously been studied against lipid peroxidation and GSH alterations for its hepatoprotective activity (Rivera et al., 2008). The study has also shown that feeding rats with resveratrol alone has a normal effect on the previous parameters which indicate the safety of using resveratrol. Resveratrol administration showed restorative effects on hydroxyproline concentration in liver tissues (Hong et al., 2010) as well as in the present study. As expected, DMN treatment for 3 weeks resulted in the development of fibrosis, thus causing the accumulation of hydroxyproline and extracellular matrix.

In the present study, fibrosis, early cirrhosis, ducts proliferation, vascularization, lymphocytic infiltration, focal necrosis, hydropic degeneration of hepatocytes, steatosis, as well as portal hypertension, all these were histopathological manifestations occurred due to DMN intoxication. Administration of resveratrol before DMN treatment has remarkably diminished all these histopathological alterations and accelerated regeneration of parenchymal cells.

Inflammatory activity in fibrosis can be divided into two main components; the first involves portal tracts with variable extension into periportal regions, the second involves liver parenchyma (Vollmar and Menger, 2009). In the present study, both areas were affected. Balloning of hepatocytes or hydropic damage and necrosis are probably reflects a defect in the membrane permeability due to ROS from DMN treatment. These changes were markedly reduced by resveratrol pre-treatment which means that resveratrol has probably counteracted the pathological effect of DMN on liver tissue. In this study, bile ducts proliferation owing to ducts obstruction, impeded bile flow which in turn caused proliferation of ductules at the edge of portal tracts. Inflammatory damage to the bile ducts may cause cholestasis and damage to hepatocytes. Portal hypertension resulted from an increase in vascular resistance and an elevated portal blood flow owing to vascular obstruction within the liver (Alan et al., 2002). Portal hypertension is a common clinical syndrome associated with chronic liver diseases. In the present study, occasional capillaries are blocked, portal hypertension has occurred in response to muscular hypertrophy of portal vein branches. In the present study histopathological alterations include, the hepatic cell plates have been destroyed and there is marked disarray and destruction of hepatocytes, many hepatocytes being atrophic. Bridging necrosis is more severe form of the inflammation. The portal tracts are enlarged and infiltrated with inflammatory cells which extended into the lobule accompanied by necrosis of individual hepatocytes. The present study proved that in the liver sections of resveratrol pre-supplemented rats, thickening of the collagen fibers was significantly reduced. Surprisingly, fat accumulation in the veins, ducts, and hepatocytes was highly eliminated, lymphocytic infiltration and necrosis was markedly reduced. All these characteristics of resveratrol depicting the potential antifibrotic role of resveratrol. Histological architecture was remarkably saved. Using resveratrol pretreatment, the progression of fibrosis was halted, and the liver function was greatly preserved.

In conclusion the present study proved that resveratrol possesses strong potentials as a promising antifibrotic and hepatoprotective agent through boosting up antioxidant defense, alleviating

oxidative stress, thus maintaining structural integrity of biomembranes and banning steatosis as well as fibrosis of liver, declaring great potentials in the prevention of fibrosis. Resveratrol ability to suppress proliferation of cells as well as reduces portal pressure, necrosis, steatosis, and liver fibrosis suggesting it may be used as a useful dietary supplement in the prevention of portal hypertension, jaundice, lipidosis and liver fibrosis.

Acknowledgment

This work was supported by a grant No. 58-37-from King Abdulaziz City for Science and Technology, Riyadh, Saudi Arabia.

References

- Ahmad, A., Afroz, N., Gupta, U.D., Ahmad, R., 2014. Vitamin B12 supplement alleviates N-nitrosodimethylamine-induced hepatic fibrosis in rats. *Pharm. Biol.* 52, 516–523.
- Ahmad, A., Ahmad, R., 2014. Resveratrol mitigate structural changes and hepatic stellate cell activation in N'-nitrosodimethylamine-induced liver fibrosis via restraining oxidative damage. *Chem. Biol. Interact.* 221, 1–12.
- Ahmad, R., Ahmed, S., Khan, N.U., Hasnain, A., 2009. *Operculina turpethum* attenuates N-nitrosodimethylamine induced toxic liver injury and clastogenicity in rats. *Chem. Biol. Interact.* 181, 145–153.
- Alan, S., Lowe, J.S., Young, B., 2002. *Wheater's Basic Histopathology: A Color Atlas and Text*. Elsevier, Churchill Livingstone, Edinburgh.
- Al-Attar, A.M., Al-Retha, H.A., 2016. Chemoprotective effect of omega-3 fatty acids on thioacetamide induced hepatic fibrosis in male rats. *Saudi J. Biol. Sci.* (in press)
- Bancroft, J.D., Gamble, M., 2002. In: Bancroft, J.D., Gamble, M. (Eds.). *Theory and Practice of Histological Techniques*, fifth ed. Churchill Livingstone.
- Bataller, R., Brenner, D.A., 2005. Liver fibrosis. *J. Clin. Invest.* 115, 209–218.
- Bergmeyer, H.U., Scheibe, P., Wahlefeld, A.W., 1978. Optimization of methods for aspartate aminotransferase and alanine aminotransferase. *Clin. Chem.* 24, 58–73.
- Birben, E., Sahiner, U.M., Sackesen, C., Erzurum, S., Kalayci, O., 2012. Oxidative stress and antioxidant defense. *World Allergy Organ. J.* 5, 9.
- Borriello, A., Cucciolla, V., Della Ragione, F., Galletti, P., 2010. Dietary polyphenols: focus on resveratrol, a promising agent in the prevention of cardiovascular diseases and control of glucose homeostasis. *Nutr. Metab. Cardiovasc. Dis.* 20, 618–625.
- Bowers, G.N., McComb, R.B., 1966. A continuous spectrophotometric method for measuring the activity of serum alkaline phosphatase. *Clin. Chem.* 12, 70–89.
- Brisdelli, F., D'Andrea, G., Bozzi, A., 2009. Resveratrol: a natural polyphenol with multiple chemopreventive properties (review). *Curr. Drug Metab.* 10, 530–546.
- Chávez, E., Reyes-Gordillo, K., Segovia, J., Shibayama, M., Tsutsumi, V., Vergara, P., Moreno, M.G., Muriel, P., 2008. Resveratrol prevents fibrosis, NF- κ B activation and TGF- β increases induced by chronic CCl₄ treatment in rats. *J. Appl. Toxicol.* 28, 35–43.
- Das, S., Fraga, C.G., Das, D.K., 2006. Cardioprotective effect of resveratrol via HO-1 expression involves p38 map kinase and PI-3-kinase signaling, but does not involve NF κ B. *Free Radic. Res.* 40, 1066.
- Docherty, J.J., McEwen, H.A., Sweet, T.J., Bailey, E., Booth, T.D., 2007. Resveratrol inhibition of *Propionibacterium acnes*. *J. Antimicrob. Chemother.* 59, 1182–1184.
- Doumas, B.T., Kwok-Cheung, P.P., Perry, B.W., Jendrzczak, B., McComb, R.B., Schaffer, R., Hause, L.L., 1985. Candidate reference method for determination of total bilirubin in serum: development and validation. *Clin. Chem.* 31, 1779–1789.
- Fan, G., Tang, J.J., Bhadauria, M., Nirala, S.K., Dai, F., Zhou, B., Li, Y., Liu, Z.L., 2009. Resveratrol ameliorates carbon tetrachloride-induced acute liver injury in mice. *Environ. Toxicol. Pharmacol.* 28, 350–356.
- Floreani, M., Napoli, E., Quintieri, L., Palatini, P., 2003. Oral administration of trans-resveratrol to guinea pigs increases cardiac DT-diaphorase and catalase activities, and protects isolated atria from menadione toxicity. *Life Sci.* 72, 2741–2750.
- Forbes, S.J., Parola, M., 2011. Liver fibrogenic cells. *Best Pract. Res. Clin. Gastroenterol.* 25, 207–217.
- Friedman, S.L., 2003. Liver fibrosis—from bench to bedside. *J. Hepatol.* 38, 38–53.
- Gao, Z.-B., Hu, G.-Y., 2005. Trans-resveratrol, a red wine ingredient, inhibits voltage-activated potassium currents in rat hippocampal neurons. *Brain Res.* 1056, 68–75.
- Giannini, E., Botta, F., Fasoli, A., Romagnoli, P., Mastracci, L., Ceppa, P., Comino, I., Pasini, A., Rizzo, D., Testa, R., 2001. Increased levels of γ GT suggest the presence of bile duct lesions in patients with chronic hepatitis C. *Dig. Dis. Sci.* 46, 524–529.
- Hong, S.-W., Jung, K.H., Zheng, H.-M., Lee, H.-S., Suh, J.-K., Park, I.-S., Lee, D.-H., Hong, S.-S., 2010. The protective effect of resveratrol on dimethylnitrosamine-induced liver fibrosis in rats. *Arch. Pharm. Res.* 33, 601–609.

- Jeong, J.-K., Moon, M.-H., Bae, B.-C., Lee, Y.-J., Seol, J.-W., Kang, H.-S., Kim, J.-S., Kang, S.-J., Park, S.-Y., 2012. Autophagy induced by resveratrol prevents human prion protein-mediated neurotoxicity. *Neurosci. Res.* 73, 99–105.
- Jin, F., Wu, Q., Lu, Y.-F., Gong, Q.-H., Shi, J.-S., 2008. Neuroprotective effect of resveratrol on 6-OHDA-induced Parkinson's disease in rats. *Eur. J. Pharmacol.* 600, 78–82.
- Khurana, S., Venkataraman, K., Hollingsworth, A., Piche, M., Tai, T.C., 2013. Polyphenols: benefits to the cardiovascular system in health and in aging. *Nutrients* 5, 3779–3827.
- Kisseleva, T., Brenner, D.A., 2006. Hepatic stellate cells and the reversal of fibrosis. *J. Gastroenterol. Hepatol.* 21, S84–S87.
- Lee, E.-S., Lee, H.-E., Shin, J.-Y., Yoon, S., Moon, J.-O., 2003. The flavonoid quercetin inhibits dimethylnitrosamine-induced liver damage in rats. *J. Pharm. Pharmacol.* 55, 1169–1174.
- Lee, E.-S., Shin, M.-O., Yoon, S., Moon, J.-O., 2010. Resveratrol inhibits dimethylnitrosamine-induced hepatic fibrosis in rats. *Arch. Pharm. Res.* 33, 925–932.
- Lee, U.E., Friedman, S.L., 2011. Mechanisms of hepatic fibrogenesis. *Best Pract. Res. Clin. Gastroenterol.* 25, 195–206.
- Li, Z., Pang, L., Fang, F., Zhang, G., Zhang, J., Xie, M., Wang, L., 2012. Resveratrol attenuates brain damage in a rat model of focal cerebral ischemia via up-regulation of hippocampal Bcl-2. *Brain Res.* 1450, 116–124.
- Muriel, P., Escobar, Y., 2003. Kupffer cells are responsible for liver cirrhosis induced by carbon tetrachloride. *J. Appl. Toxicol.* 23, 103–108.
- Ndiaye, M., Philippe, C., Mukhtar, H., Ahmad, N., 2011. The grape antioxidant resveratrol for skin disorders: promise, prospects, and challenges. *Arch. Biochem. Biophys.* 508, 164–170.
- Ohkawa, H., Ohishi, N., Yagi, K., 1979. Assay for lipid peroxides in animal tissues by thiobarbituric acid reaction. *Anal. Biochem.* 95, 351–358.
- Parola, M., Pinzani, M., 2009. Hepatic wound repair. *Fibrogen. Tissue Repair* 2, 1.
- Rajesh, M.G., Latha, M.S., 2004. Preliminary evaluation of the antihepatotoxic activity of Kamilarī, a polyherbal formulation. *J. Ethnopharmacol.* 91, 99–104.
- Reddy, J.K., Rao, M.S., 2006. Lipid metabolism and liver inflammation. II. Fatty liver disease and fatty acid oxidation. *Am. J. Physiol. Liver Physiol.* 290, G852–G858.
- Rivera, H., Shibayama, M., Tsutsumi, V., Perez-Alvarez, V., Muriel, P., 2008. Resveratrol and trimethylated resveratrol protect from acute liver damage induced by CCl₄ in the rat. *J. Appl. Toxicol.* 28, 147–155.
- Rosen, D.R., Siddique, T., Patterson, D., Figlewicz, D.A., Sapp, P., Hentati, A., Donaldson, D., Goto, J., O'Regan, J.P., Deng, H.-X., others, 1993. Mutations in Cu/Zn superoxide dismutase gene are associated with familial amyotrophic lateral sclerosis. *Nature* 362, 59–62.
- Rosen, H.R., Keeffe, E.B., 2000. Evaluation of abnormal liver enzymes, use of liver test, and the serology of viral hepatitis. *Liver Dis. Diagnosis Manage.*, 24–35.
- Sharma, S., Kulkarni, S.K., Chopra, K., 2007. Effect of resveratrol, a polyphenolic phytoalexin, on thermal hyperalgesia in a mouse model of diabetic neuropathic pain. *Fundam. Clin. Pharmacol.* 21, 89–94.
- Shetty, A.K., 2011. Promise of resveratrol for easing status epilepticus and epilepsy. *Pharmacol. Ther.* 131, 269–286.
- Singh, N., Pillay, V., Choonara, Y.E., 2007. Advances in the treatment of Parkinson's disease. *Prog. Neurobiol.* 81, 29–44.
- Solans, A., Zambrano, A., Rodriguez, M., Barrientos, A., 2006. Cytotoxicity of a mutant huntingtin fragment in yeast involves early alterations in mitochondrial OXPHOS complexes II and III. *Hum. Mol. Genet.* 15, 3063–3081.
- Sugimoto, K., Takei, Y., 2017. Pathogenesis of alcoholic liver disease. *Hepatol. Res.* 47, 70–79.
- Thirunavukkarasu, M., Penumathsa, S.V., Koneru, S., Juhasz, B., Zhan, L., Otani, H., Bagchi, D., Das, D.K., Maulik, N., 2007. Resveratrol alleviates cardiac dysfunction in streptozotocin-induced diabetes: role of nitric oxide, thioredoxin, and heme oxygenase. *Free Radic. Biol. Med.* 43, 720–729.
- Tietze, F., 1969. Enzymic method for quantitative determination of nanogram amounts of total and oxidized glutathione: applications to mammalian blood and other tissues. *Anal. Biochem.* 27, 502–522.
- Timmers, S., Auwerx, J., Schrauwen, P., 2012. The journey of resveratrol from yeast to human. *Aging (Albany, NY)* 4, 146–158.
- Ungvari, Z., Bagi, Z., Feher, A., Recchia, F.A., Sonntag, W.E., Pearson, K., De Cabo, R., Csiszar, A., 2010. Resveratrol confers endothelial protection via activation of the antioxidant transcription factor Nrf2. *Am. J. Physiol. Circ. Physiol.* 299, H18–H24.
- Vollmar, B., Menger, M.D., 2009. The hepatic microcirculation: mechanistic contributions and therapeutic targets in liver injury and repair. *Physiol. Rev.* 89, 1269–1339.
- Wallerath, T., Deckert, G., Ternes, T., Anderson, H., Li, H., Witte, K., Förstermann, U., 2002. Resveratrol, a polyphenolic phytoalexin present in red wine, enhances expression and activity of endothelial nitric oxide synthase. *Circulation* 106, 1652–1658.
- Wegwu, M.O., Ayalogu, E.O., Sule, O.J., 2005. Anti-oxidant protective effects of Cassia alata in rats exposed to carbon tetrachloride. *J. Appl. Sci. Environ. Manage.* 9, 77–80.
- WHO, 2002. Concise International Chemical Assessment. Document 38 (N-Nitrosodimethylamine). Geneva, Switz.
- Zhou, K., Lu, L.G., 2009. Assessment of fibrosis in chronic liver diseases. *J. Dig. Dis.* 10, 7–14.